

DOI: <https://doi.org/10.32652/spmed.2019.1.92-98>

## Clinical features of disruption in reciprocal inhibition of facial muscles-antagonists as justification for application of rehabilitation programs in patients with long-standing Bell's palsy

УДК 796.616.8

**A. Pashov<sup>1</sup>, I. Zharova<sup>2</sup>**

<sup>1</sup>Crystal Touch Bell's Palsy clinic, Rotterdam, The Netherlands

<sup>2</sup>National University of Physical Education and Sport of Ukraine, Kyiv, Ukraine

**Abstract. Objective.** To identify disruption in reciprocal inhibition of facial muscles-antagonists as possible cause for their simultaneous co-contractions during spontaneous and voluntary mimetic movements in patients with long-standing Bell's palsy and to justify the application of rehabilitation programs in the process of recovery for such patients. **Methods.** To analyze the dynamics of co-contractions in muscle pairs m.levator palpebrae superioris-m.orbicularis oculi pars palpebralis, m.frontalis-m.orbicularis oculi pars orbitalis and mm.zygomatici-m.depressor anguli oris et m.mentalis. To investigate disruption of reciprocal inhibition of m.levator palpebrae superioris as a possible contributor to the forming of ocular-oral synkinesis. **Results.** Disruption of reciprocal inhibition of m.levator palpebrae superioris during spontaneous blinking and voluntary eye closure in patients with long-standing Bell's palsy causes over-amplification of contraction signals from the motor cortex in the direction of m.orbicularis oculi pars palpebralis and often results in incomplete closure of eye fissure. This disruption probably also contributes to the forming of ocular-oral synkinesis.

**Keywords:** Bell's palsy, facial palsy complications, facial synkinesis, facial muscles, reciprocal inhibition

**Клінічні особливості порушення реципрокного гальмування лицьових м'язів-антагоністів як обґрунтування для застосування програм реабілітації пацієнтів з давнім невідновленим паралічем Белла**

**О. Пашов<sup>1</sup>, І. Жарова<sup>2</sup>**

<sup>1</sup>Crystal Touch Bell's Palsy clinic, Роттердам, Нідерланди

<sup>2</sup>Національний університет фізичного виховання і спорту України, Київ, Україна

**Резюме. Мета.** Визначити порушення в реципрокному гальмуванні лицьових м'язів-антагоністів як можливу причину їхніх спільних скорочень під час спонтанних та вільних мімічних рухів у пацієнтів з неповністю відновленим паралічем Белла, та обґрунтувати застосування програм реабілітації в процесі відновлення таких пацієнтів. **Методи.** Проаналізувати динаміку спільних скорочень у парах м'язів: м'яз – підіймач верхньої повіки – коловий м'яз ока (повікова частина), лобовий м'яз – коловий м'яз ока (очноямкова частина) і виличний м'яз – м'яз – опускач кута рота і підборідний м'яз. Дослідити порушення реципрокного гальмування м'яза – піднімача верхньої повіки як можливого фактора, що сприяє формуванню повіко-губної синкінезії. **Результати.** Порушення реципрокного гальмування м'яза – піднімача верхньої повіки при спонтанному морганні і довільному заплещуванні очей у пацієнтів з неповністю відновленим паралічем Белла викликає надмірне посилення скорочувальних сигналів від кори головного мозку в напрямку колового м'яза (повікової частини) і часто призводить до неповного закриття очної щілини. Це порушення, ймовірно, також сприяє формуванню повіко-губної синкінезії.

**Ключові слова:** параліч Белла, неврит лицьового нерва, синкінезії, мімічні м'язи, реципрокне гальмування

**Клинические особенности нарушения реципрокного торможения лицевых мышц-антагонистов как обоснование для применения программ реабилитации пациентов с давним невосстановленным параличом Белла**

**А. Пашов<sup>1</sup>, И. Жарова<sup>2</sup>**

<sup>1</sup>Crystal Touch Bell's Palsy clinic, Роттердам, Нидерланды

<sup>2</sup>Национальный университет физического воспитания и спорта Украины, Киев, Украина

**Резюме.** Цель. Определить нарушение реципрокного торможения лицевых мышц-антагонистов как возможную причину их совместных сокращений при спонтанных и произвольных мимических движениях у пациентов с неполностью восстановленным параличом Белла и обосновать применение программ реабилитации в процессе восстановления таких пациентов. Методы. Проанализировать динамику совместных сокращений в парах мышц: мышца, поднимающая верхнее веко – круговая мышца глаза (вековая часть), лобная мышца – круговая мышца глаза (глазничная часть) и скуловые мышцы – мышца, опускающая угол рта и подбородочная мышца. Исследовать нарушение реципрокного торможения мышцы, поднимающей верхнее веко, как возможного фактора, содействующего формированию веко-губной синкинезии. Результаты. Нарушение реципрокного торможения мышцы, поднимающей верхнее веко, при спонтанном моргании и произвольном закрытии глаза у пациентов с неполностью восстановленным параличом Белла вызывает чрезмерное усиление сократительных сигналов от коры головного мозга в направлении круговой мышцы глаза (вековой части) и часто приводит к неполному закрытию глазной щели. Это нарушение, вероятно, также способствует формированию веко-губной синкинезии.

**Ключевые слова:** паралич Белла, неврит лицевого нерва, синкинезии, мимические мышцы, реципрокное торможение

**Introduction**

Despite that idiopathic peripheral neuropathy of facial nerve (Bell's palsy) is the second most common disorder of peripheral nervous system, the mechanisms of forming of complications after long-standing Bell's palsy remain mostly unclear. One of the most common complications of Bell's palsy as well as other peripheral facial palsies of various etiologies is facial synkinesis [1, 12].

At present, there are several theories about possible causes of facial synkinesis.

- Nuclear hyperexcitability [9]
- Ephaptic transmission [15]
- Aberrant regeneration of facial nerve [8]

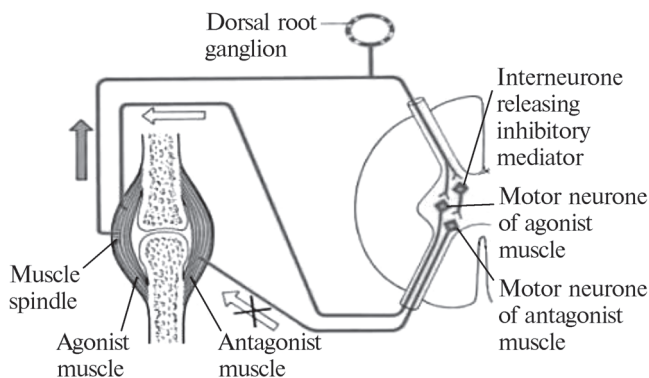
Without going into detail of those theories, in this article we will analyze one of the aspects of disruption in normal functioning of facial muscles,

namely a disruption of reciprocal inhibition of mimetic muscles-antagonists during long recovery after Bell's palsy and deviations from natural mimetic patterns related to this irregularity.

Reciprocal inhibition is the automatic antagonist alpha motor neuron inhibition which is evoked by contraction of the agonist muscle. This so-called natural reciprocal inhibition is a ubiquitous and pronounced phenomenon in man and must be suspected of playing a major role in the control of voluntary movements [4, 5].

We should note that the research of reciprocal inhibition till now had focused on studies of skeletal muscles that have muscle spindles, which provide sensory feedback and participate in proprioception. Studies of mimetic proprioception and respectively of reciprocal inhibition of facial muscles up till now did not attract many researchers. Probably, the reason is that this object is rather challenging to study on animal models, and that disruptions of facial movements after peripheral neuropathies of facial nerve, although represent a huge aesthetic problem for the patients, do not nevertheless present any immediate danger to general health or to life of such patients [7].

This article is aimed at giving a start to the study of this issue and attracting attention of researchers to the necessity of deeper and more detailed studies of mechanisms of mimetic proprioception, as well as of the problems related to disruption of natural mimetic patterns in patients



**Fig. 1** – Scheme of reciprocal inhibition of muscle-antagonist by contraction of muscle-agonist [16]

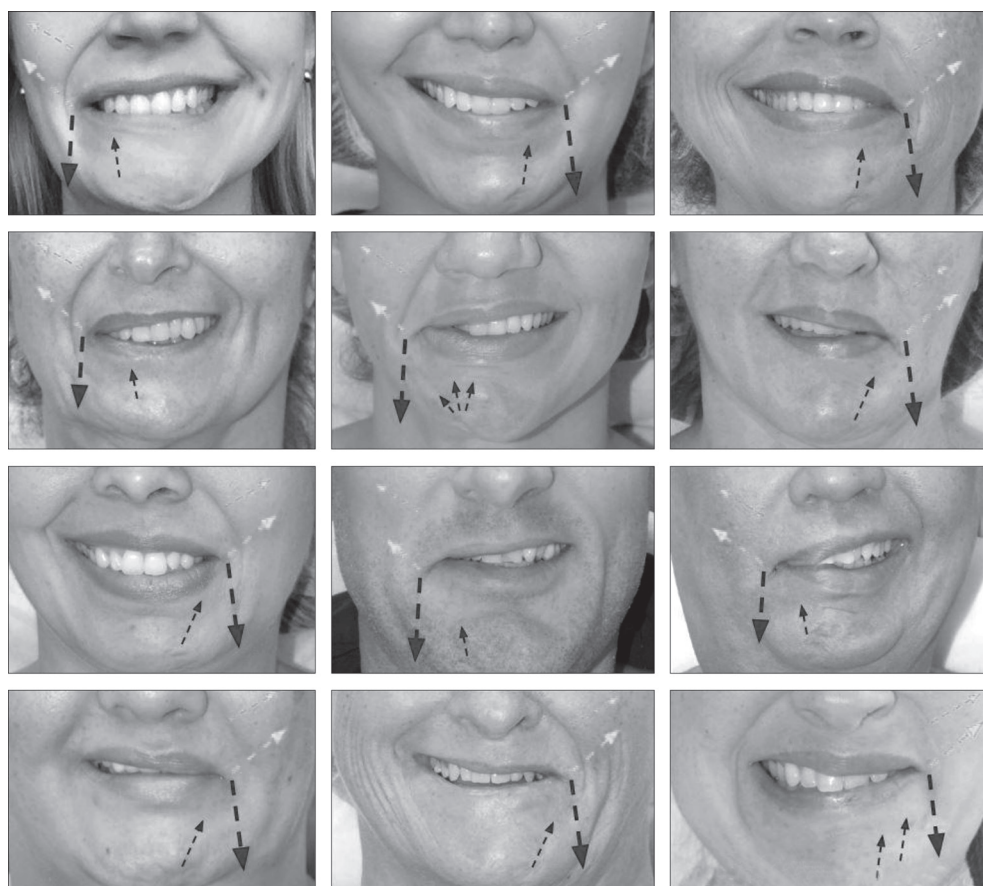
with long-standing Bell's palsy. The idea behind suggested additional studies is to improve our understanding of deep-rooted causes of Bell's palsy complications and to search for optimal, efficient and economical methods of rehabilitation that will allow to achieve long-lasting improvements of patients' facial movements and of their quality of life.

**Background**

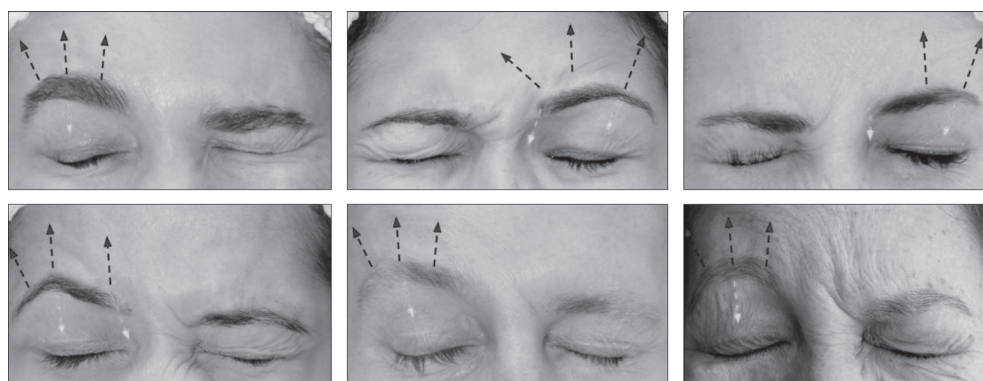
While analyzing the neurological tests (photos of 13 standard facial expressions) of patients who approached Crystal Touch clinic for rehabilitation of residuals and complications of long-standing Bell's palsy, we observed that in most cases, along with

the "classical" manifestations – synkinesis and contractures of facial muscles, there are also present simultaneous co-contractions of facial muscles in pairs agonist-antagonist. Particularly, in pairs *m.levator palpebrae superioris* – *m.orbicularis oculi pars palpebralis*, *m.frontalis* – *m.orbicularis oculi pars orbitalis* and *mm.zygomatici* – *m.depressor anguli oris et m.mentalis*.

For example, when the patient tries to smile, together with his *mm.zygomaatici (major et minor)* will also simultaneously contract their antagonist – *m.depressor anguli oris* and partly – chin muscle (*m.mentalis*). As a result of the opposition



**Fig. 2** – Dimples in the chin and immobile mouth corner during attempt of broad smile. Green arrows show contraction vectors of zygomatic muscles, blue arrows show contraction vectors of *m.depr.anguli oris* and certain fibers of *m.mentalis*.



**Fig. 3** – Disruption of reciprocal inhibition of *m.frontalis* during eye squinting. Blue arrows show force vectors of *m.frontalis*, green arrows show contraction vectors of *m.orbicularis oculi pars orbitalis*.

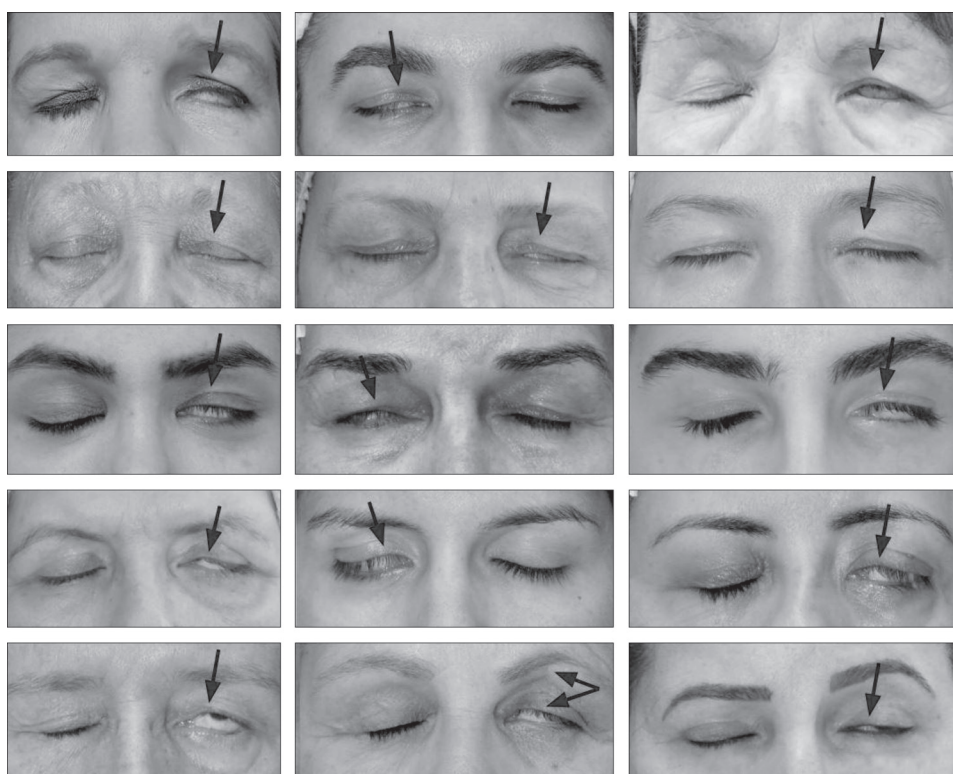of muscles-antagonists, lateral excursion of the mouth corner in such patients is very limited, if at all. At the same time, resulting from static tension of *m.depressor anguli oris* and of chin muscle (*m.mentalis*), some dimples will form in the chin on the affected side from contractions of certain fibers of respective muscles.

Another example. As the patient tries to squint her eyes, together with orbital part of *m.orbicularis oculi*, involuntarily contracts also its antagonist – frontal muscle. Force vectors of these muscles compensate each other, which results in the eyebrow either remaining static or even elevate a little. Result – the eye does not squint, although the upper eyelid usually fully closes (except severe cases with insufficient reinnervation of the palpebral part of *m.orbicularis oculi*).

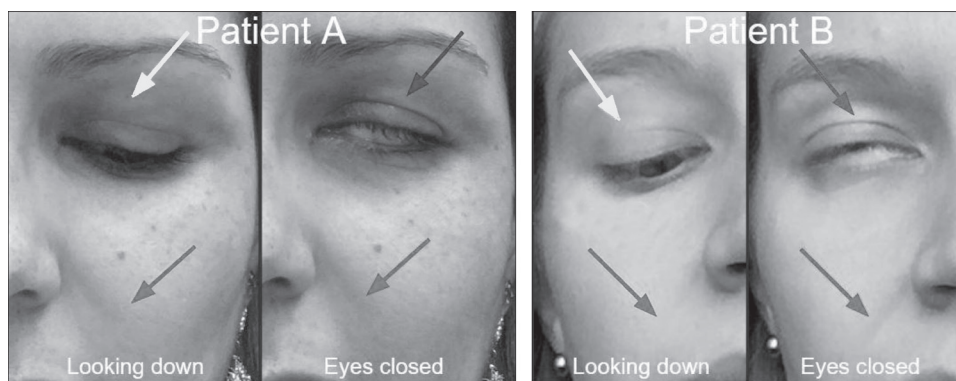
### Discussion

Let us consider in more detail possible forming mechanism for suchlike disruption of normal mimetic patterns on an example of the pair *m.levator palpebrae superioris* – *m.orbicularis oculi pars palpebralis*.

During blinking or voluntary eye closure in many patients with long-standing Bell's palsy, we can observe incomplete closure of eye fissure, which is accompanied by Bell's phenomenon – involuntary rollup of the eyeball. Along with this, we have observed that on the affected side, the upper eyelid undergoes characteristic deformation in the attachment area of *m.levator palpebrae superioris* and there also remains a fold in the upper eyelid, which we do not observe on the healthy side when eyes are closed.



**Fig. 4** – Affected eye closed with Bell's phenomenon and eyelid deformation



**Fig. 5** – Eye closed voluntarily (red arrows show Bell's phenomenon and ocular-oral synkinesis) and "Look down" test (green arrows show absence of irregularities)

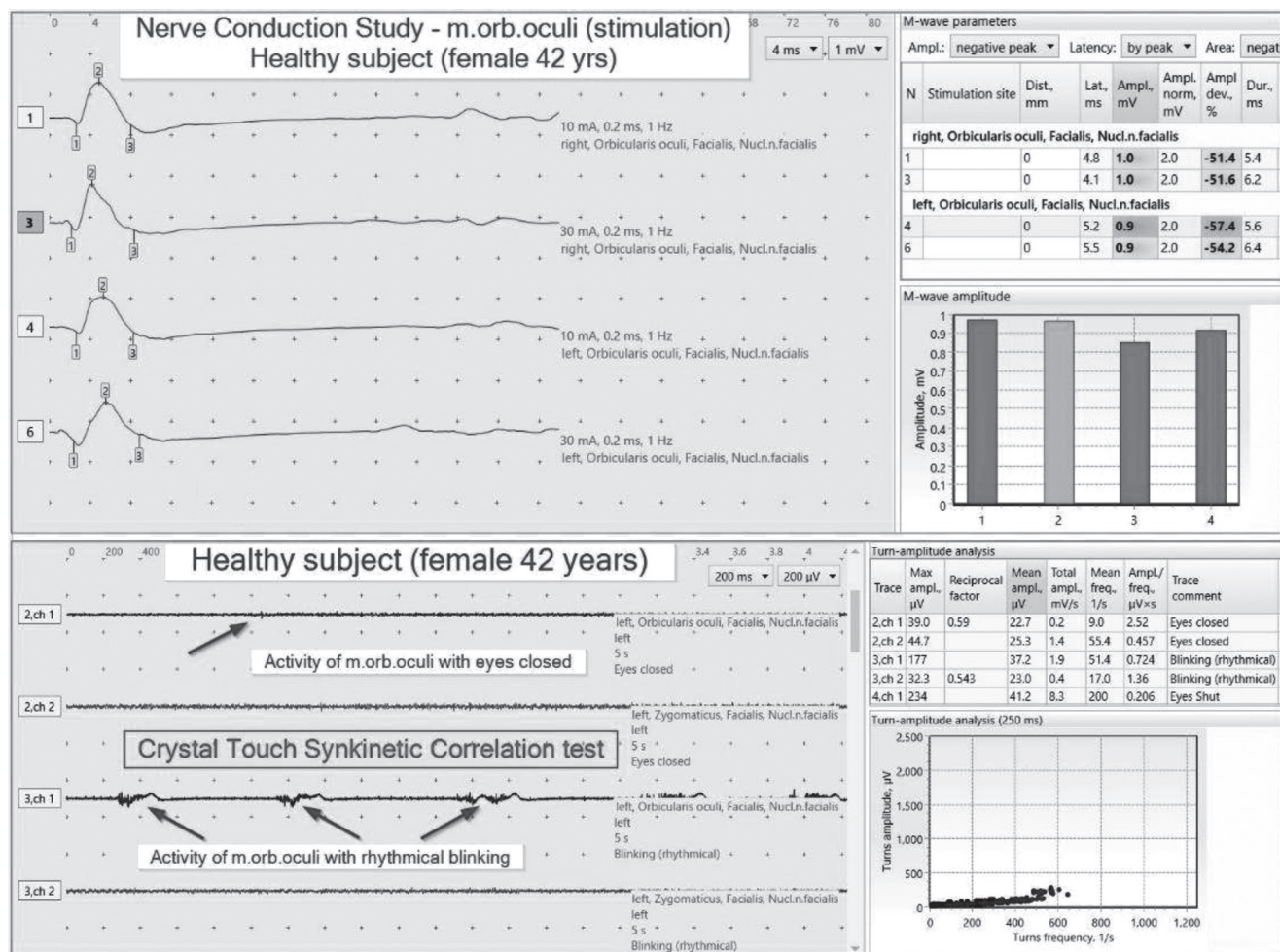


Fig. 6 – NCS and Synkinetic Correlation test for m.orbicularis oculi (healthy subject)

At the same time, when we did the mimetic test “Look down” with most of the same patients, their upper eyelid would descend symmetrically with the healthy side, without deformation and without forming the asymmetric fold.

The analysis of this phenomenon allowed us to suggest that in these patients develops an impairment of relaxation reflex for *m.levator palpebrae superioris* in case of voluntary eye closure, whereas the same reflex remains intact in case of looking down, allowing the upper eyelid to follow the eyeball downward without any difficulty and without eyelid deformation or Bell’s phenomenon. Evidently, in the case of eye closure, initiation of reciprocal inhibition involves neural circuits of facial nerve (*n.facialis*, CN VII), and in the case of looking down – neural circuits of oculomotor nerve (*n.oculomotoris*, CN III), where muscle that lifts the upper eyelid (*m.levator palpebrae superioris*) belongs [8, 14].

Results of Nerve Conduction Study [2, 3, 6, 9, 10] of *m.orbicularis oculi* in majority of our patients with long-standing Bell’s palsy usually demonstrate considerable recovery of its innervation – from 70

to 95% compared to the healthy side. Considering that upper eyelid is small in size, in such cases the downward force generated by palpebral part of *m.orbicularis oculi* should be more than sufficient to fully close the eye fissure, provided that there is no external resistance.

Results of Crystal Touch Synkinetic Correlation test [10] demonstrate that to close the eye or to blink the patient with long-standing Bell’s palsy exerts 2-3 times more efforts by circular muscle of the eye compared to his healthy side, or compared to the same test conducted for healthy subjects. Despite high level of tension in the circular muscle of the eye (*m.orbicularis oculi*), eye fissure closure on the affected side in such patients is often incomplete, Bell’s phenomenon is often observed and ocular-oral synkinesis is practically always present.

Further analysis of the data from instrumental measurements and pictures of neurological tests (13 standard facial expressions) allowed us to conclude that the most probable cause of incomplete

eye fissure closure during voluntary eye closure and blinking is the disruption of reciprocal inhibition of *m.levator palpebrae superioris* (antagonist of *m.orbicularis oculi pars palpebralis*). Under normal functioning of reciprocal inhibition, once the muscle-agonist contracts, the muscle-antagonist reflexively relaxes from inhibitory signals arriving via its motor nerve. To provide execution of this mechanism, corresponding neural circuits of CNS are engaged.

In cases of long-standing Bell's palsy, as soon as the patient attempts to blink or to close the eye voluntarily, together with contraction of *m.orbicularis oculi pars palpebralis* which closes the upper eyelid, also contracts *m.levator palpebrae superioris* which is trying to open the upper eyelid at the same time, thus resisting the intended facial movement. The mechanism of mimetic proprioceptive feedback results in increase of contraction signal generated by motor cortex in the direction of the muscle that closes the upper eyelid. At the same time involuntarily occurs an increase in contraction force of the muscle that opens the upper eyelid and so on. Finally, the efforts by

both antagonists reach (sub)maximal values that fully or partly compensate each other. Resulting closure of eye fissure may be complete or incomplete, depending on the impairment level of reciprocal inhibition of *m.levator palpebrae superioris* in particular patient, and on reinnervation level of *m.orbicularis oculi pars palpebralis*.

Practically in all patients with long-standing Bell's palsy we observe ocular-oral synkinesis of various intensities which manifests itself during blinking or voluntary eye closure [1]. From our point of view, this synkinesis may be regarded as a kind of "side effect" of disruption in reciprocal inhibition of *m.levator palpebrae superioris*.

In our opinion, the forming mechanism of synkinesis can be described as follows.

1. While generating mimetic contraction signals of maximal intensity under the conditions of impaired reciprocal inhibition of antagonist muscle that resists intended movement, the area of motor cortex corresponding to the muscle-agonist reaches high level of excitation. This excitation may spread to the adjacent areas that are responsible for functioning of other facial muscles [13].

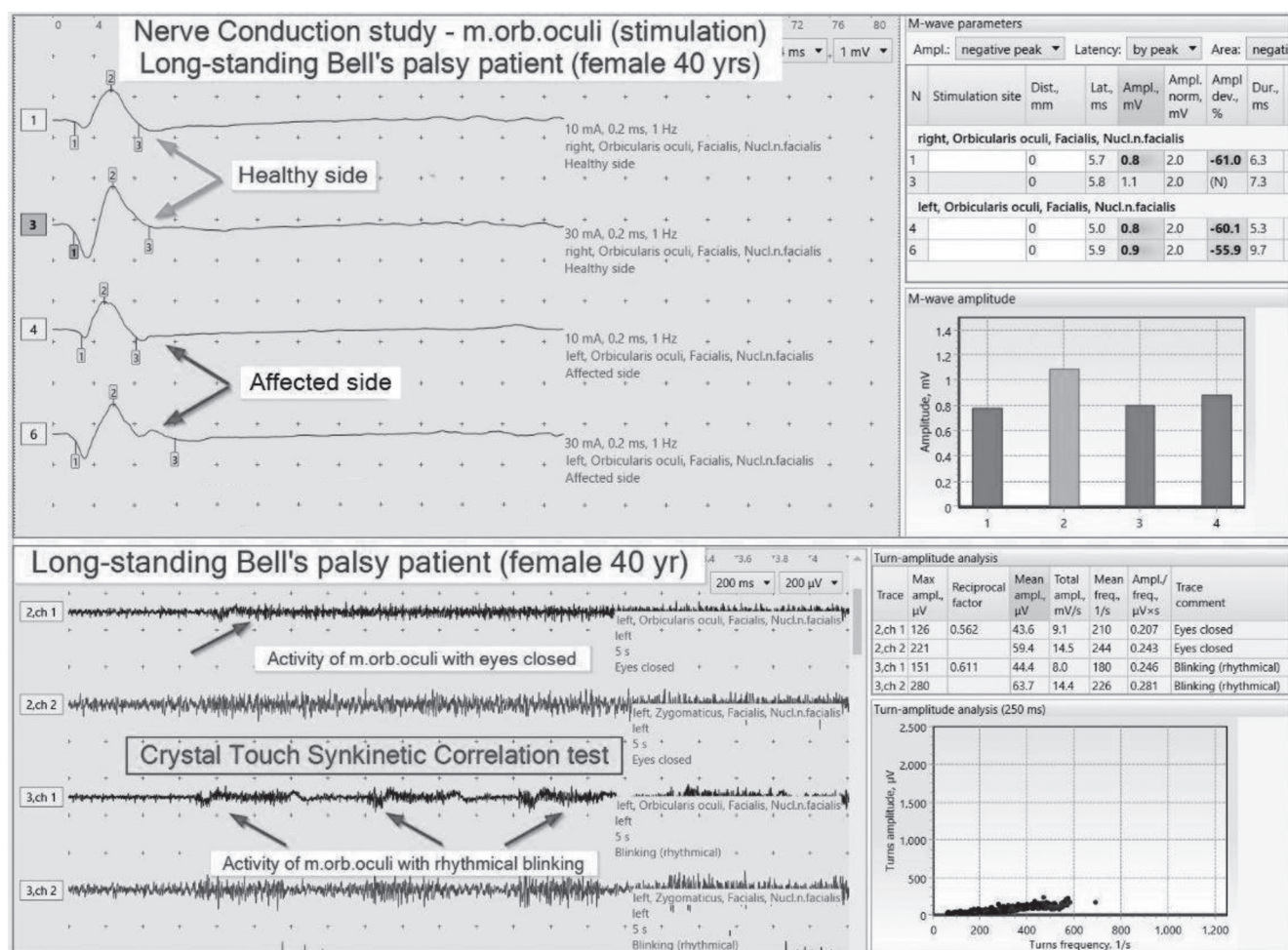


Fig. 7 – NCS and Synkinetic Correlation test for m.orbicularis oculi (long-standing Bell's palsy patient)

2. With two antagonists “wrestling” for the management of the upper eyelid, some “parasite” contraction signals may be generated by those newly-excited motor cortex areas in the direction of zygomatic muscles.

3. Contraction of these muscles results in twitching of the mouth corner when the patient blinks or closes the eyes.

It is remarkable that if the patient looks down or closes his eyelid with a finger, there are no synkinetic contractions of zygomatic muscles observed, even if later the finger is removed and the upper eyelid remains in a closed position. Sometimes, after the closing finger is removed, the upper eyelid begins to open involuntarily from the residual tension in *m.levator palpebrae superioris*. Synkinetic contractions of zygomatic muscles in such case occur only if the patient exerts voluntary efforts to keep the upper eyelid closed.

### Conclusions

In the course of long recovery, due to countless repetitions of eye blinking, the above-described mechanism gradually consolidates. It transforms from voluntary into an involuntary, automatic form,

### References

1. Azizzadeh Babak, and Slattery III William H.: The Facial Nerve – New York: Thieme Medical Publishers, 2014.
2. Basmajian John V., Deluca Carlo J. Muscles Alive: Their Functions Revealed by Electromyography – Baltimore : Williams & Wilkins, 1985.
3. Buschbacher Ralph, Kumbhare Dinesh, Robinson Lawrence. Buschbacher’s Manual of Nerve Conduction Studies, Third Edition. – New York : Demos Medical Publishing, 2016.
4. Carpenter Roger, and Reddi Benjamin. Neurophysiology. A conceptual approach. Fifth edition. London: Hodder Arnold, 2012.
5. Crone C. «Reciprocal inhibition in man». *Dan Med Bull.* 1993; 40 (5):571–81.
6. Douglas W, Beck and James W. Hall III. Evaluation of the facial nerve via electroneuronography (ENoG). *The Hearing Journal.* 2001; 54(3):36-44.
7. Henkelmann T. Physical therapy and neuromuscular rehabilitation. In: May M, Schaitkin BM. The Facial Nerve. 2nd Ed. New York, NY: Thieme; 2000:301-19.

and solidifies into a new dynamic mimetic pattern in the neural circuits of CNS. This way, thanks to neuroplasticity [13] the patient’s brain forms a new, pathological synkinetic dynamic stereotype that probably has at its foundation disruption of reciprocal inhibition of *m.levator palpebrae superioris*.

This mimetic habit is, at its core, a conditioned reflex [11], which results in excitation of motor cortex areas that are responsible for contraction of *mm.zygomatici major et minor*, and as the trigger for its execution may serve either the intention of CNS to do the act of automatic blinking or a voluntary effort of a patient to close his eyes.

Good news, in our opinion is that as any other conditioned reflex, synkinetic mimetic patterns can be gradually deactivated with negative feedback (remember Pavlov’s dogs). In this case it can be a gradual and conscious replacement by the patient his dominant for facial muscle contractions by the new dominant for their relaxation (inhibition). More detailed consideration of this topic lies outside the scope of this article and will be addressed in a separate study.

8. Kimura Jun. Electrodiagnosis in Diseases of Nerve and Muscle. Principles and Practice. – New York: Oxford University Press, 2013.
9. Moran CJ, Neely JG. Patterns of facial nerve synkinesis. *Laryngoscope.* 1996; 106(12 Pt 1):1491-96.
10. Pashov A. Nerve conduction study in rehabilitation of patients with residuals and complications of long-standing Bell’s palsy. Fundamental and applied researches in practice of leading scientific schools. 2018; 27 (3): 39-45.
11. Pashov A. Paradigm shift in rehabilitation of long-standing Bell’s palsy during later stages of recovery. Fundamental and applied researches in practice of leading scientific schools. 2018; 26 (2): 294-98.
12. Pietersen E. The natural history of Bell’s palsy. *Am. J. Otol.* 1982;4(2):107-111.
13. Presti David E. Foundational Concepts of Neuroscience. – New York : W.W. Norton & Company, 2016.
14. Rusk H. Rehabilitation medicine. – St.Louis: Mosby, 1977. – 675 p.
15. Sadjadpour K. Postfacial palsy phenomena: faulty nerve regeneration or ephaptic transmission? *Brain Res.* 1975; 95(2-3):403-06.
16. <https://byebyedoctor.com/reciprocal-inhibition/>